

# MALARIA IN CHIMPANZEES IN SIERRA LEONE

BY

S. ADLER

(Received for publication 15 November, 1922)

## PLATES II AND III

Reichenow (1920) working in the Cameroons, found parasites indistinguishable from human malaria parasites in the blood of gorillas and chimpanzees. Of eight chimpanzees examined six were found to be infected, one with *Plasmodium vivax* ? forms (gametocytes only), two with *Plasmodium falciparum* forms (crescents only), one with *P. falciparum* and *P. vivax* forms, and two with *P. falciparum* and *P. vivax* forms together with *P. malariae* forms.

Reichenow found that infections were heaviest in young animals, and suggested that resistance is acquired after attacks in early life.

Blacklock and Adler (1922), of the Liverpool School of Tropical Medicine, described a parasite resembling *Plasmodium falciparum* in a chimpanzee, and forms resembling *P. vivax* and *P. malariae* also occurred, but the only form of gametocyte found was the crescent.

I have recently examined thirteen additional chimpanzees, six of which were caught near Pendembu, and six near Blama, in the Sierra Leone Protectorate, and one from an unknown locality.

Of these thirteen animals, two were found to be infected with parasites indistinguishable from *P. falciparum*. The infected cells were not enlarged or pale, and many of the delicate rings showed two bars of chromatin. In both cases crescents were found, but only after prolonged search, resembling in this respect human infections with *P. falciparum* in West Africa. Parasites resembling simple tertian or quartan forms were not found.

CASE I. Captured near Blama. The animal was emaciated and weak. A blood examination on 8th September, 1922, showed numerous rings and a few crescents. On 9th September, 1922, quinine hydrochloride, 0.5 grains, was administered intramuscularly; rings were present in the blood until 14th September, 1922, but crescents persisted until the animal's death on 2nd October, 1922.

The animal's condition showed no marked improvement after the disappearance of rings from the peripheral blood; its appetite was poor and it often passed loose stools containing a large amount of fat globules. Death occurred after an attack of enteritis, which was apparently caused by an invasion of *Oxyuris* sp., of which large numbers (all immature) were passed in the animal's stool.

Post-mortem, malaria pigment was found in the spleen, liver, and bone marrow, and crescents, in small numbers, in the bone marrow. The liver showed fatty changes. Enormous numbers of immature *Oxyuris* were found in the large intestine.

25th September, 1922. Advantage was taken of the fact that rings had not been seen in the blood for eleven days, and that crescents still persisted, to test the theory of parthenogenesis. 0.4 c.c. of the animal's blood were injected into another chimpanzee in which malaria parasites had never been found since it first came under observation on 4th September, 1922.

The injected animal was observed till the 11th November, 1922, but parasites were not found in the peripheral blood.

CASE II. Captured near Pendembu. The animal was extremely emaciated. On 12th September, 1922, rings and crescents were found, but the infection gradually disappeared without treatment, and on the 19th September, 1922, the blood became negative. The animal's condition gradually became worse, it took very little food, the stools were loose and always contained fat globules.

On 30th October, 1922, the blood examination again showed a few ring-form parasites.

The animal died on 30th October, 1922. Post-mortem pigment was found in the spleen and bone marrow, and a small number of schizonts in the spleen; no crescents were found. The liver was pale, and on section showed extreme fatty degeneration and infiltration, the majority of the liver cells being destroyed.

It is interesting to note that both animals were young (under two years). Older animals, including one old adult, were negative. This supports Reichenow's suggestion that in chimpanzees, as in natives, resistance is acquired after attacks in early life.

#### THE RELATIONSHIP OF MALARIA IN CHIMPANZEES TO HUMAN MALARIA IN SIERRA LEONE

Although the malaria parasite in the chimpanzee in Sierra Leone is morphologically indistinguishable from *P. falciparum*, there is as yet no evidence that it is this species.

Mesnil (1920) failed to infect a chimpanzee by intravenous injections of human blood infected with *P. falciparum*. He also failed to infect the same chimpanzee by the bite of Anophelines with sporozoites of *Plasmodium falciparum* in their salivary glands.

Blacklock and Adler (1922) failed to infect:—

(1) Two Europeans by intravenous and subcutaneous injections of heavily infected blood from a chimpanzee.

(2) A chimpanzee by an injection of 3 c.c. of blood heavily infected with *P. falciparum* from a patient during his first attack of malaria, which he acquired in Sierra Leone.

(3) *Anopheles costalis* by feeding on a chimpanzee; but it should be noted that crescents were scanty in the animal's blood.

The existence of a relationship between human malaria and malaria in chimpanzees cannot be conclusively proved or disproved, until the insect vector of the latter be discovered and experiments with the infective vector carried out on human beings.

My best thanks are due to Mr. W. Addison, Provincial Commissioner of Kennema, and Mr. N. C. Hollins, District Commissioner of Pendembu, through whose kindness I obtained a number of chimpanzees.

#### SUMMARY AND CONCLUSIONS

Thirteen chimpanzees were examined for malaria in Sierra Leone.

Two young animals were found to be infected with a parasite indistinguishable from *P. falciparum*.

Older animals were negative, and resistance following attacks in early life is, therefore, suggested.

Blood from one chimpanzee containing only crescents failed to infect another chimpanzee.

Both infected animals on post-mortem examination showed fatty changes in the liver.

#### REFERENCES

- BLACKLOCK and ADLER (1922). A Parasite resembling *Plasmodium falciparum* in a chimpanzee. *Ann. Trop. Med. & Parasit.*, Vol. XVI, No. 1, pp. 99-106.
- MESNIL, F., and ROUBAUD, E. (1920). Essais d'inoculation du paludisme au chimpanzé. *Ann. Inst. Past.*, Vol. XXXIV, No. 7, pp. 467-479.
- REICHENOW, E. (1920). Ueber das Vorkommen der Malaria Parasiten des Menschen bei den Afrikanischen Menschenaffen. *Centralblatt f. Bakteriologie*. Abt. Originale. Vol. LXXXV, No. 3, pp. 207-216.

EXPLANATION OF PLATE II

Malaria Parasites.

Figs. 1 to 17. Ring forms.

Figs. 18 to 19. Crescents.



## EXPLANATION OF PLATE III

- Fig. 1. Micro-photograph of liver (Case II), showing fatty degeneration and infiltration.  $\times 250$ .
- Fig. 2. On the right, young chimpanzee with malaria, showing emaciation. (Note absence of paunch.)  
On the left, healthy young animal.

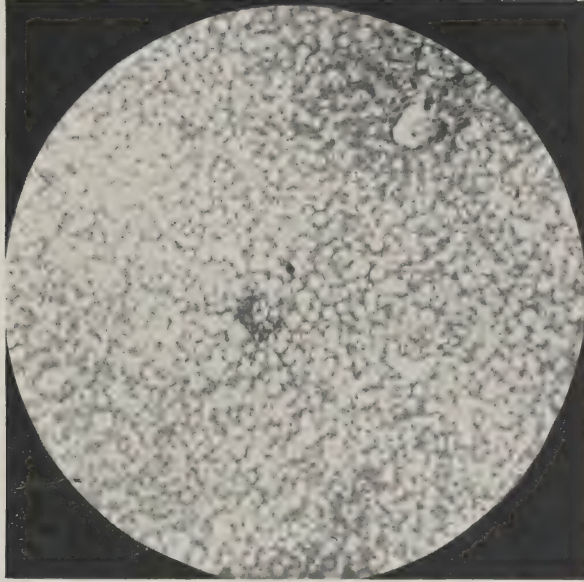


FIG. 1



FIG. 2